

بِسْمِ اللَّهِ الرَّحْمَنِ الرَّحِيمِ



By

DR:FARIED Mohammed WAGDY  
(MD)

MENOFIA UNIVERSITY

Although BCVA remains the gold standard assessment tool for measuring visual function, it is widely recognized that conventional tests of vision, such as high-contrast BCVA, underestimate the actual level of visual impairment, particularly in older patients.

- As a result, other clinical assessment tools, such as contrast sensitivity, macular recovery function, and reading speed tests, are often employed to assess visual function in an individual, particularly when measuring changes in visual function after an intervention.

- Although the Humphrey Field Analyzer (HFA) can be used to assess central macular sensitivity, its role in monitoring macular disease has been limited by its inability to quantify retinal thresholds accurately over small and discrete retinal lesions and to retest these areas accurately over time.

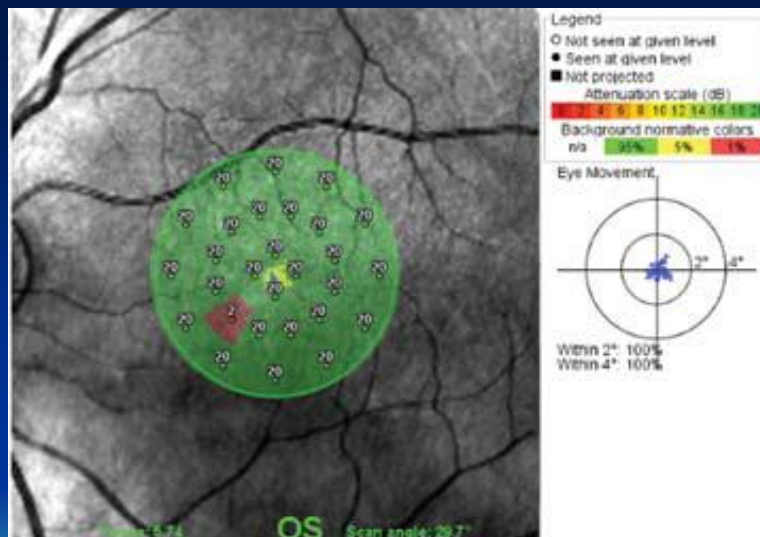
- In response to these limitations, the scanning laser ophthalmoscope (SLO) microperimeter was developed. The SLO integrates fundus imaging with computerized threshold perimetry to achieve an exact correlation between macular and corresponding functional defects .

- The desire for a more practical, user-friendly alternative led to the development of the Nidek MP1 microperimeter. That incorporates a color fundus camera for image registration and an auto-tracking system to facilitate the accurate measurement of retinal sensitivity within the central visual field, even in patients with unstable or extrafoveal fixation.

- Microperimetry literally means perimetry over a small area of retina, and this function allows you to establish retinal stimulus threshold in areas that have been scanned. When microperimetry is carried out, the patient is asked to fixate and then press a button if stimuli of varying intensity
- are presented within a defined area of their vision.

- The machine can then establish retinal function within this area. There are several programs to choose from, the simplest being four stimuli around fixation, while other programs include a peripapillary assessment and a modified 10-2 screening.

- As might be expected, patients maintain fixation better with the shorter programs, especially if the testing is being performed as part of an overall OCT assessment.



- a data plot from a simple central scan showing a missed point and also the fixation tracker which helps you to check on patient reliability

- It adds much useful functional information to the anatomical data and will help you to better monitor the impact of progressive eye diseases.

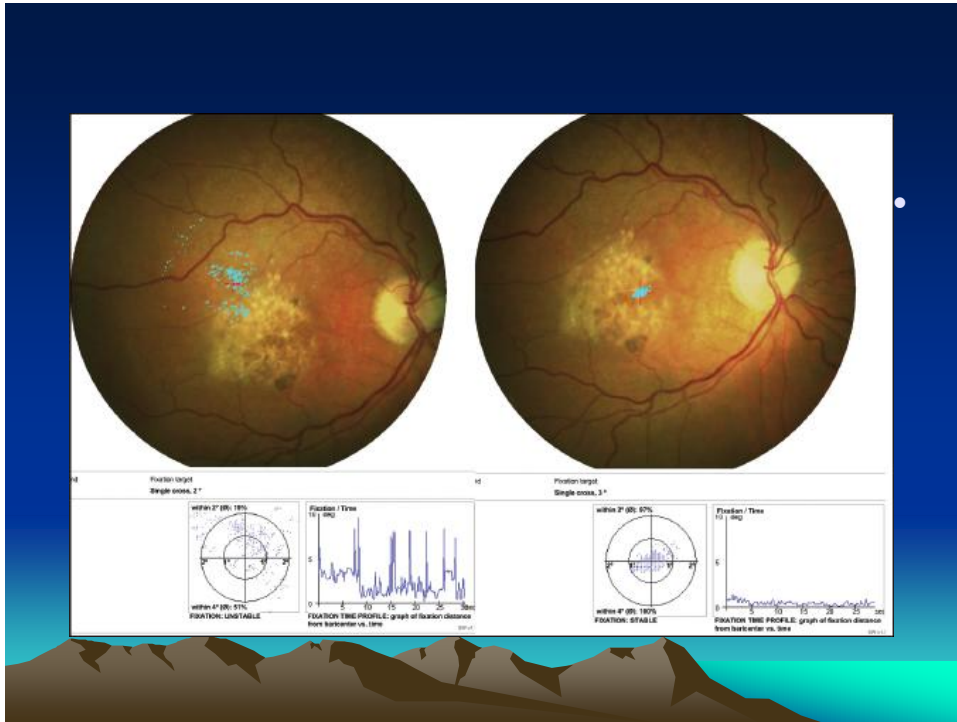
- **THE ASSESSMENT OF FIXATION PATTERNS**

The study of fixation patterns is beginning to receive attention from investigators, who are using them to measure visual performance and to understand and develop strategies for rehabilitating patients with macular disease.

During testing, autotracking within the MP1 detects and measures patients' eye movements, calculating the shifts relative to central fixation at a frequency of 25 Hz (40 ms).

- Consequently, the MP1 allows for fast, reliable microperimetric examination of fixation and scotoma characteristics in patients with macula disease, even when the visual acuity is reduced and fixation is eccentric and unstable .





- The widely accepted description of the stability and location of fixation is based upon Fujii et al.'s original classification. In brief, **the location of fixation** is defined as the position of fixation with respect to the center of the foveal avascular zone, and **stability of fixation** is defined as the ability of the eye to maintain a stable fixation in the preferred retinal locus (PRL).

- Conversely, the presence of fibrosis, RPE atrophy, and loss of foveal autofluorescence are associated with a much higher rate of unstable eccentric fixation.

- Perhaps not surprisingly then, fixation is significantly more likely to be central and stable in patients with neovascular AMD who have received treatment with ranibizumab, compared to those who have not.

- **THRESHOLD MICROPERIMETRY IN MACULAR DISEASE**

- Conventional static perimetry has long been the “gold standard” in the assessment of retinal sensitivity in the management of glaucoma. Macular microperimetry, like conventional perimetry, is a psychophysiological method that assesses retinal sensitivity.

- However, unlike convention perimetry, the automated eye-tracking system shifts the position of the stimulus to compensate for small eye movements, while larger eye movements prompt the test to pause until the patient refixates on the target. This auto-tracking and automatic registration of one test to another allow for precise microperimetric assessment of central field sensitivities.

- Conceptually, the perimetric assessment from field analyzers, such as the HFA and MP1, are similar, but important differences in stimulus configuration can produce discordant results.

- Whereas the HFA perimeter uses a projection system with a broad range of stimulus intensities, the MP1 uses a small solid-state monitor to present the targets over a limited range of intensities.

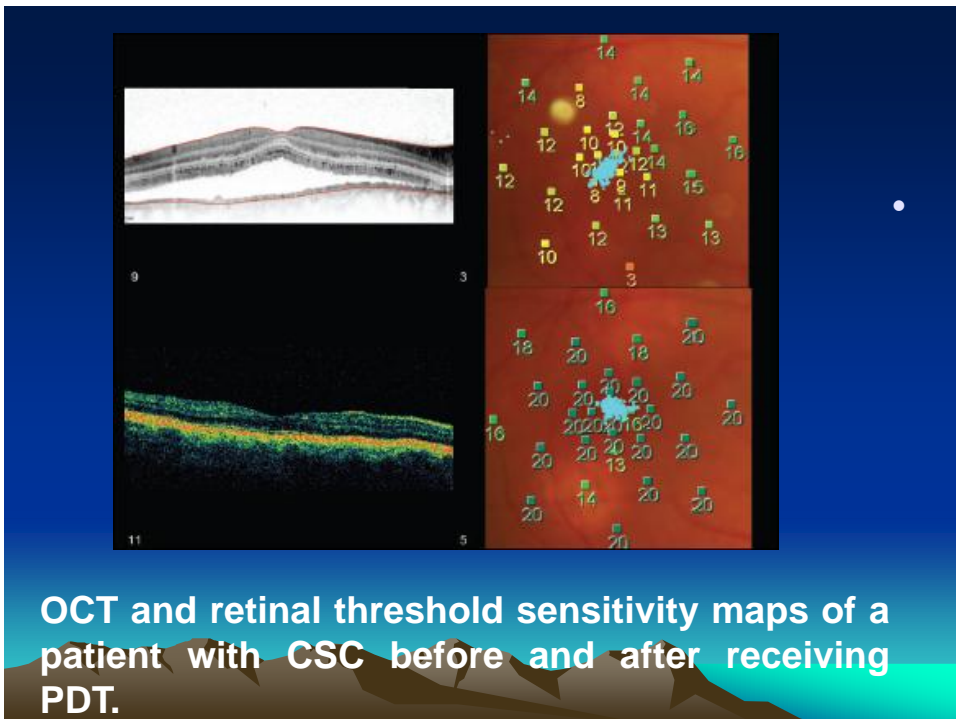
- Stimuli are presented on a background of 10 candelas per meter square ( $\text{cd}/\text{m}^2$ ) with the HFA, but on a dimmer background of  $1.27 \text{ cd}/\text{m}^2$  with the MP1. The differences in background adaptation level and minimum stimulus luminance cause a variation between the dynamic ranges of the two devices.

- Aside from this limitation, the MP1 affords the operator a great deal of flexibility in determining how the target area will be tested.

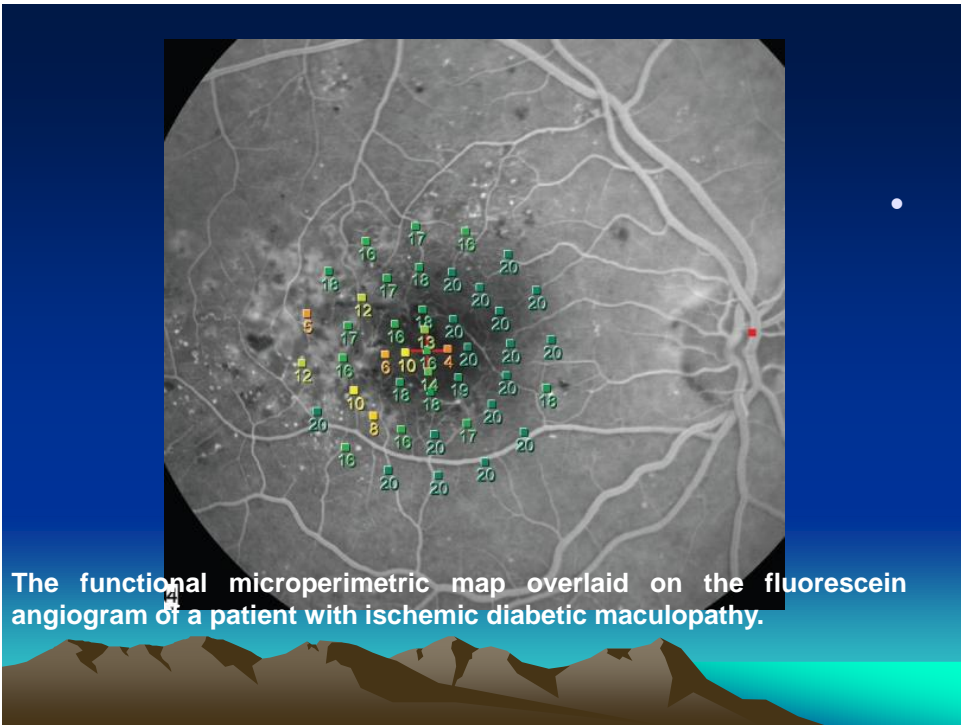
- In brief, the operator chooses from a menu of test patterns that can be projected across the target area. The operator can change the number, as well as the density, of test loci within the test polygon, which may be centered on any area of the central macula the operator chooses.

## Clinical Cases•

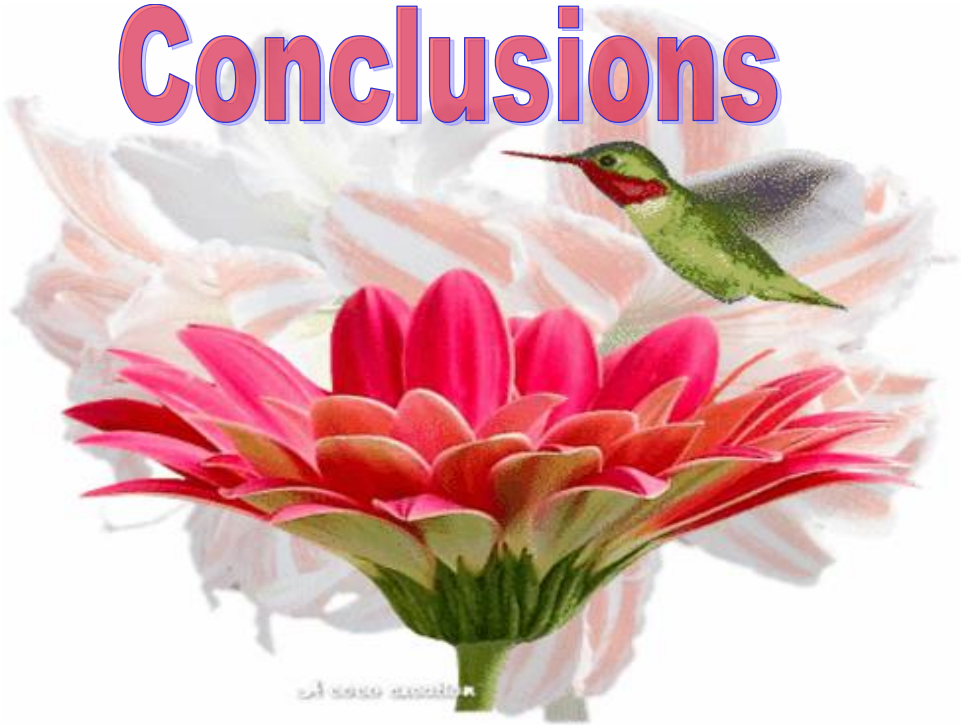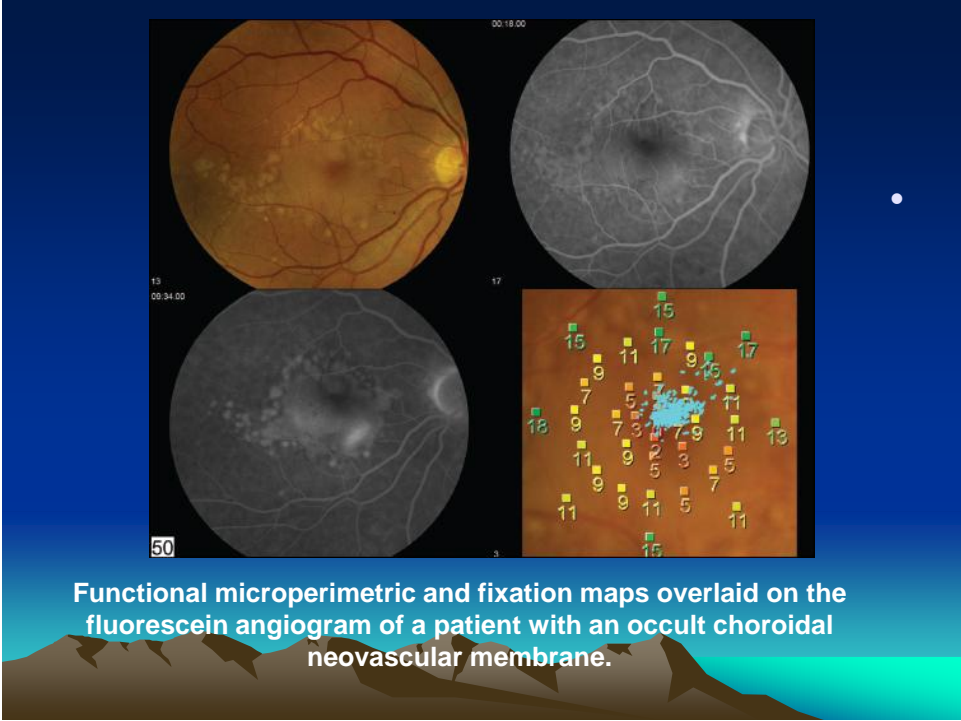
- The **color-graded figures** are the sensitivity (dB) recorded at each of the test loci. Superimposed on the MP map is the **fixation plot**. Although prior to treatment the patient had a high-contrast Snellen visual acuity of 20/30, the MP map clearly shows a large central scotoma and unstable fixation, both of which improved markedly after treatment.



The patient's visual acuity was a remarkable 20/30, suggesting that the foveal and parafoveal tissue was being maintained in a larger part by the choriocapillaris.







- In conclusion, the arrival of affordable and user-friendly automated microperimeters promises to enhance our understanding of macular disease and our assessment of future and existing treatments.

- Looking forward, perhaps the most pressing need at this time is to standardize testing strategies to allow for meaningful comparisons of reported datasets from different investigators. If such a protocol can be agreed upon, then microperimetry promises to be a powerful tool for both researchers and clinicians alike

