بسم الله الرحمن الرحيم

I.C. Trabeculectomy

E.S.G. P.A.A.G.S.

Nov 2007

- Ahmed Aboueleinein M.D.
- Ibrahim Al-Jadaan M.D.
- Ayman Salah M.D.
- Hassan Eissa M.D.

Trabeculectomy

- Objective
- Indications
- Procedure
- Problems
- Complications

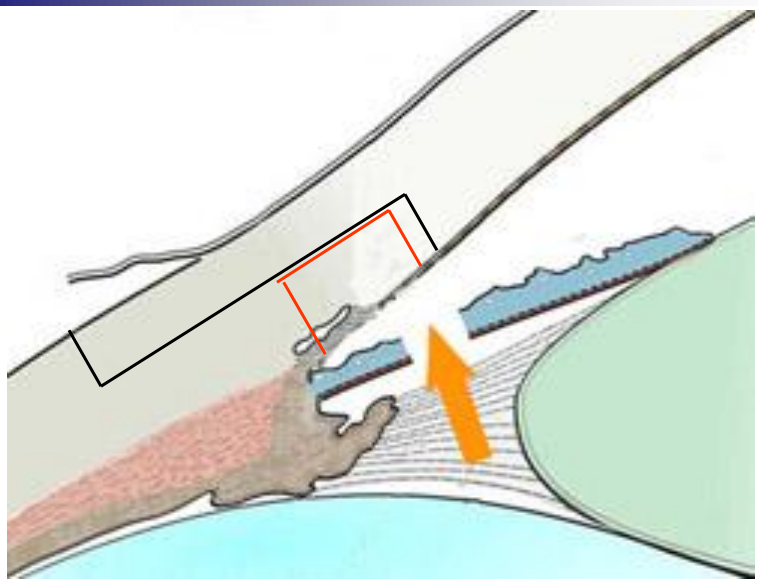

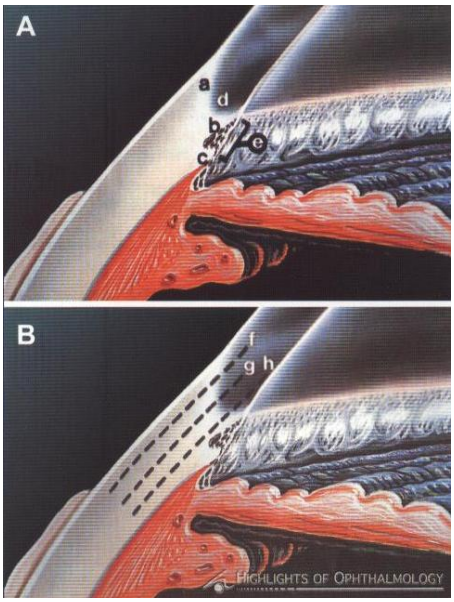
A
a
d
b
c
e
B
f
g
h
HIGHLIGHTS OF OPHTHALMOLOGY


F
A
L
C
S
HIGHLIGHTS OF OPHTHALMOLOGY

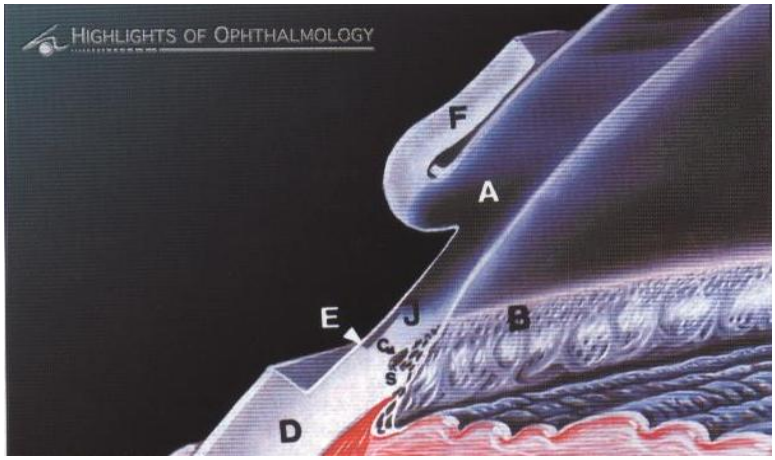
HIGHLIGHTS OF OPHTHALMOLOGY
F
A
E
J
B
D

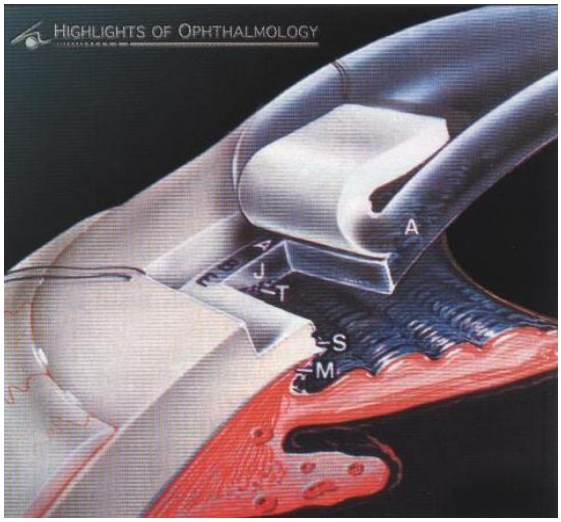
HIGHLIGHTS OF OPHTHALMOLOGY
A
J
T
S
M

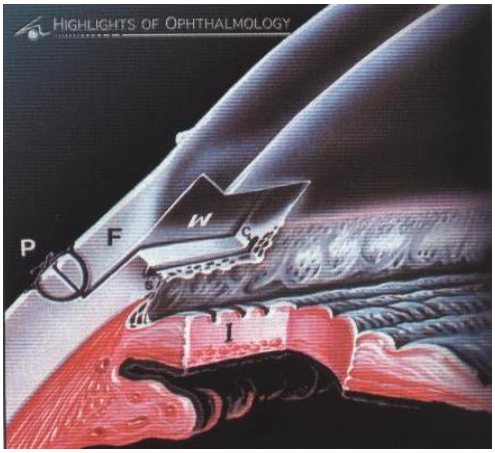

- 10 glaucoma specialists from 10 various centers in Egypt where requested to provide data about their surgical approach in Trabeculectomy and the outcome of surgery (6 months follow up)

1. Paracenthesis
2. Sutures
3. Use of antimetabolites
4. Cases controlled without additional medical treatment
5. Cases controlled with 1 or 2 drugs after surgery
6. Second surgical intervention was needed.

Participants:

1. A. Abdelshafek
2. A. Aboueleinein
3. A. Elshiaty
4. A. Khalefa
5. A. Khalil
6. E. Mohammed
7. H. Eissa
8. M. Ibrahim
9. M. Nassar
10. T. Mokbel

Fixation

Fixation

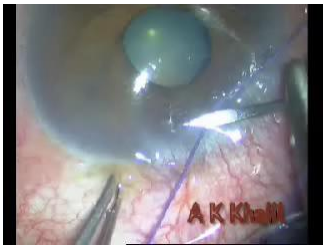

Conj. Flap

Diathermy

Scleral Flap

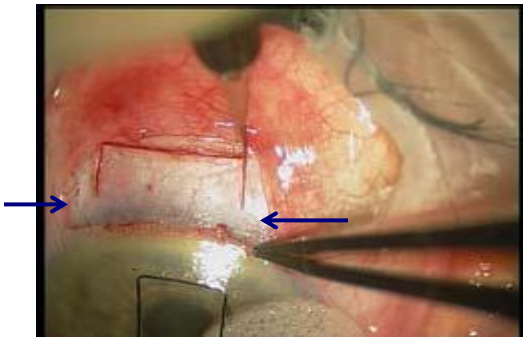

Scleral Flap

Pre-placed Sutures

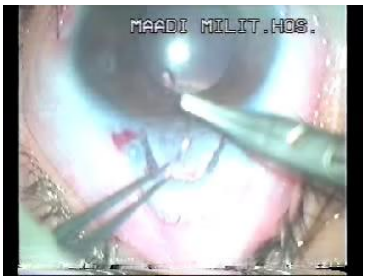

Paracenthesis

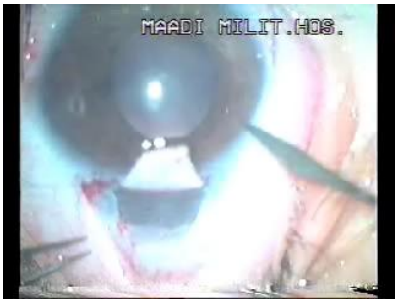

Viscoelastic

Trabeculectomy Opening

Flap Suturing

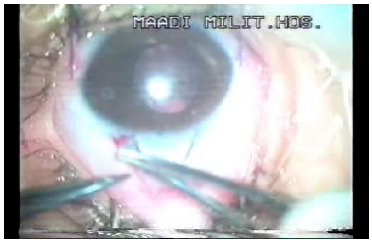

Flap Suturing

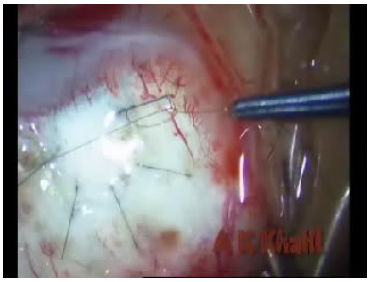

Releasable Sutures

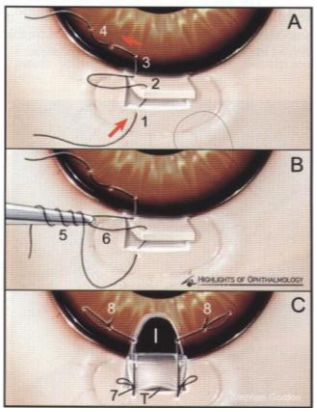

Conj. Suturing

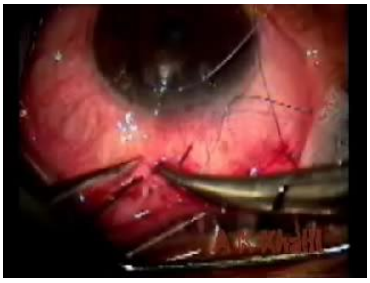

Conj. Suturing

Washing Viscoelastic

Washing Viscoelastic

Wound Healing

- What do we require?
- What is available?
- What is update?
- What about the future?

What do we require?

- Optimized wound healing
  - Aiming at target IOP
  - With no complications or at least with very low probability of complications

What is available in current use?

Antimetabolites

- Mitomycin-c
- 5-FU
- Disadvantages:
  - Hypotony
  - Very thin bleb → infection
  - Toxicity

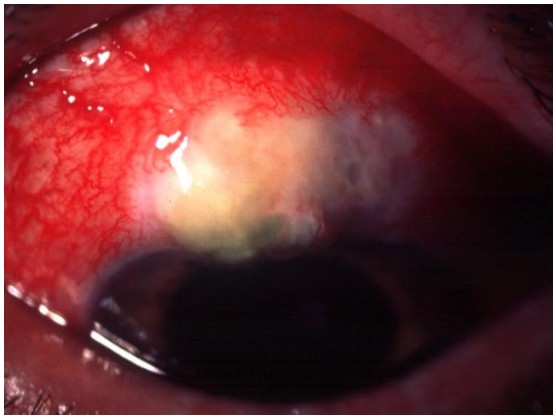

Blebitis

Optimizing the Effects of Anti-metabolites

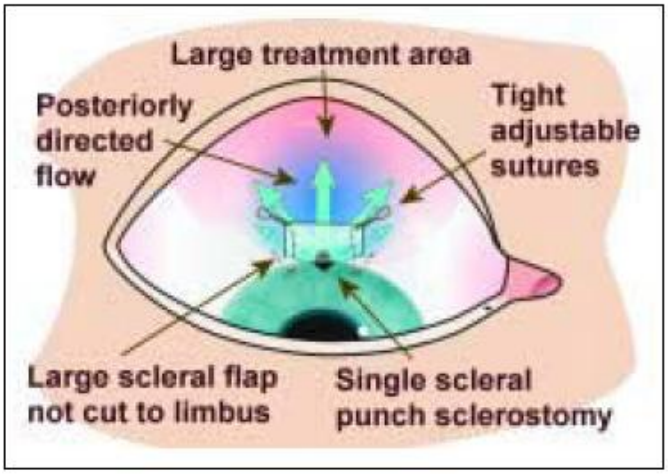

P. Khaw

TABLE 3. MOORFIELDS EYE HOSPITAL'S INTRAOPERATIVE, SINGLE-DOSE, ANTISCARRING REGIMEN*†

Patient Category	Characteristics	Regimen
Low-Risk	No risk factors Topical medications (eg, beta-blockers, pilocarpine) Afro-Caribbean origin and elderly <40 years of age with no other risk factors	Nothing or intraoperative 5-FU 50 mg/mL[††§] for 5 minutes, as per the Moorfields "More Flow" study
Intermediate-Risk	Topical medications (eg, adrenaline) Previous cataract surgery without conjunctival incision (capsule intact) Several low-risk factors Combined glaucoma filtration surgery/cataract extraction Previous conjunctival surgery (eg, squint surgery, retinal detachment surgery, trabeculotomy)	Intraoperative 5-FU 50 mg/mL[††] for 5 minutes or MMC 0.2 mg/mL[§] for 3 minutes, as per the Moorfields "More Flow" study
High-Risk	Neovascular glaucoma Chronic, persistent uveitis Previous failed trabeculectomy/tubes Chronic conjunctival inflammation Multiple risk factors Aphakic glaucoma	Intraoperative MMC 0.5 mg/mL[§] for 3 minutes (a tube may be more appropriate in many of these cases, combined with MMC)

Updates
Modulation of Wound Healing

- **Cross linked Healon**
- Implants
- Anti-VEGF
- Tubes
- Gene therapy

Surgical Modalities

- Cross linked Healon, new injection implant
  Penetrating surgery
  Non-penetrating surgery
  Viscocanalostomy



- Acts by maintaining a space between n the scleral flap and the bed

- CLX Healon stays for at least 6 months proven by UBM

Modulation of wound Healing in Glaucoma Surgery 2012
Ahmed Aboueleinein

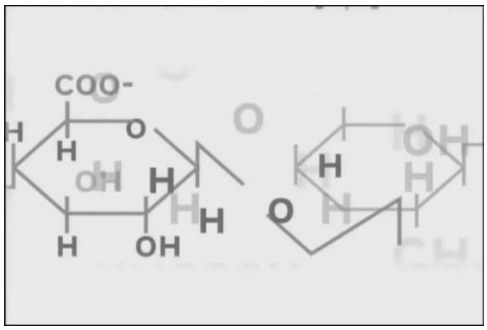

- Synthetic material of very high molecular weight
- Non animal origin

- Anti inflammatory
- Hge control
- Easy learning curve

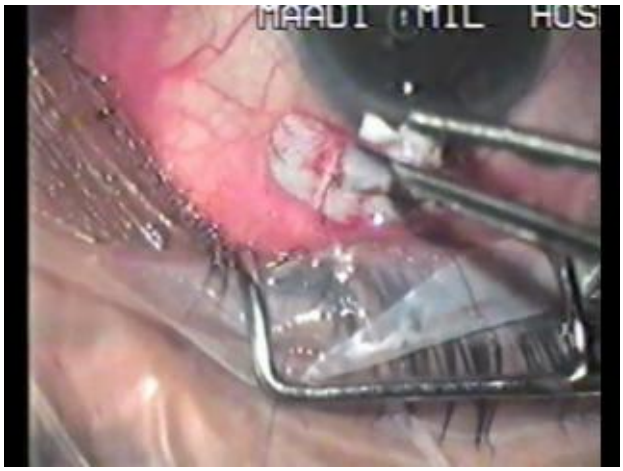

Modulation of wound Healing in
Glaucoma Surgery 2012
Ahmed Aboueleinein

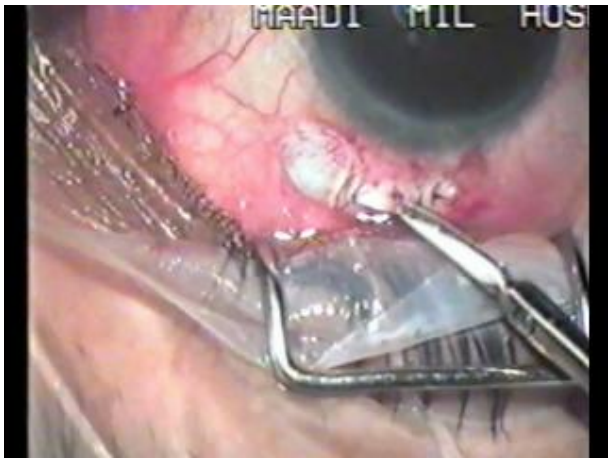

Modulation of wound Healing in
Glaucoma Surgery 2012
Ahmed Aboueleinein

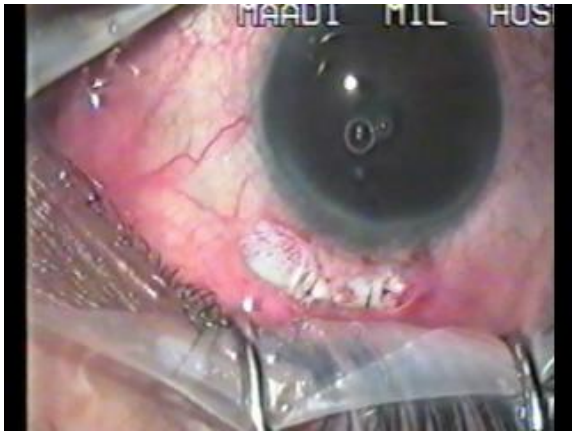

Modulation of wound Healing in
Glaucoma Surgery 2012
Ahmed Aboueleinein

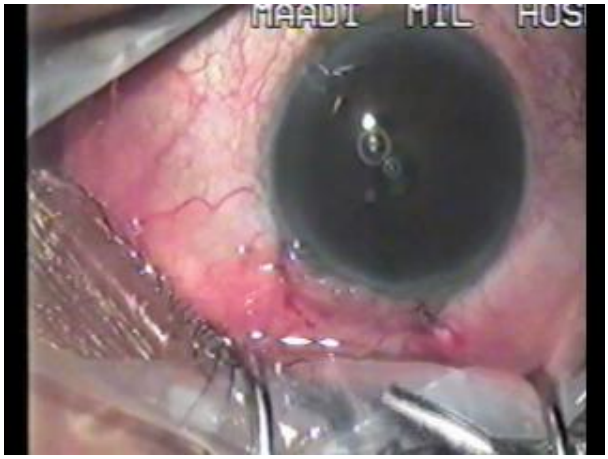

Modulation of wound Healing in
Glaucoma Surgery 2012
Ahmed Aboueleinein

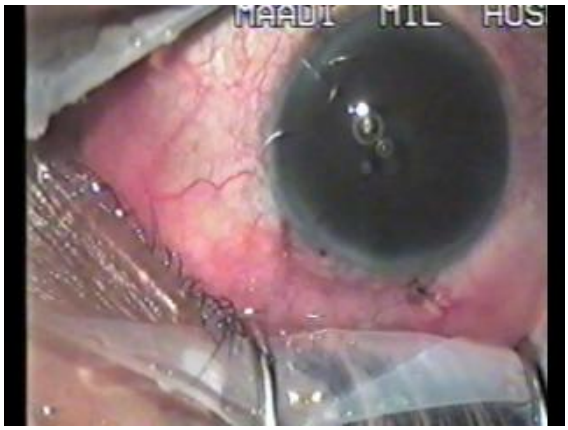

Modulation of wound Healing in
Glaucoma Surgery 2012
Ahmed Aboueleinein

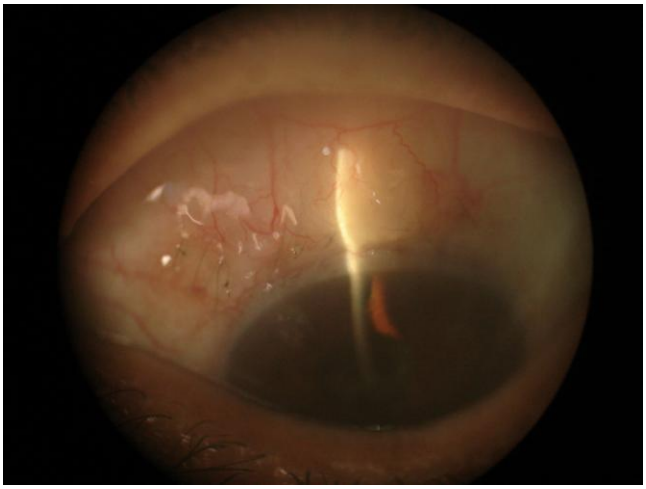

Modulation of wound Healing in
Glaucoma Surgery 2012
Ahmed Aboueleinein

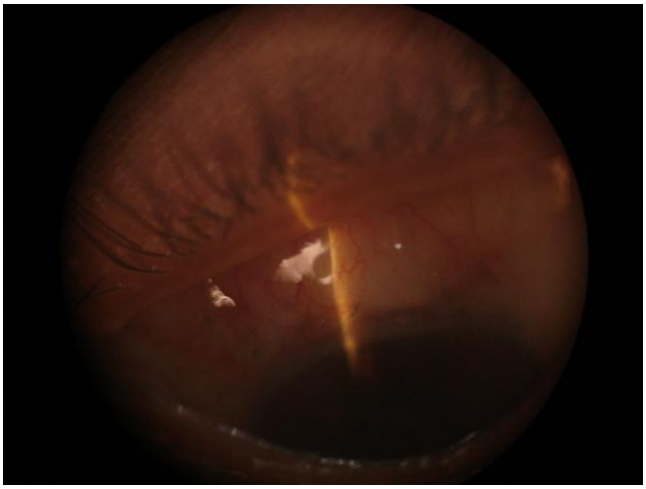

Modulation of wound Healing in
Glaucoma Surgery 2012
Ahmed Aboueleinein

Modulation of wound Healing in
Glaucoma Surgery 2012
Ahmed Aboueleinein

CLX Healon precautions

- No Healon in the AC
- Proper wash of the Healon from the edge of the conjectiva
- Proper closure of the conjectiva

Disadvatages

- Pressure spikes
- Difficult suture lysis

Modulation of wound
Healing in Glaucoma
Surgery 2012
Ahmed Aboueleinein

Cross Linked Healon

- Maintains bleb formation for a long duration
- Minimizing scare formation
- Anti- inflanatory effect
- Non animal origin

Collagen implant

- Bio-compatible material
- Acts as a highly porous scaffold that encourages random growth of fibroblasts through its pores and secretes connective tissue in the form of non scaring loose matrix

- Used in 16000 filtering surgeries

Device Description



- Type I atelocollagen with porous structure and pore diameter between 10~300μm
- Comprised >90% atelocollagen and <10% glycosaminoglycan (GAG)
- Dry form scaffold

Product

Product shape	Model	Specification
	830601	6 mm (D) × 2 mm (H)
	830621	7.5 mm (D) × 2 mm (H)
	862051	12 mm (D) × 1 mm (H)
	870041	5 mm (W) × 10 mm (L) × 4 mm (H)
	870051	10 mm (W) × 10 mm (L) × 2 mm (H)
	870061	10 mm (W) × 10 mm (L) × 4 mm (H)
	861051	12/20 mm (ID/OD) × 1 mm (H)

Modulation of wound Healing in
Glaucoma Surgery 2012
Ahmed Aboueleinein

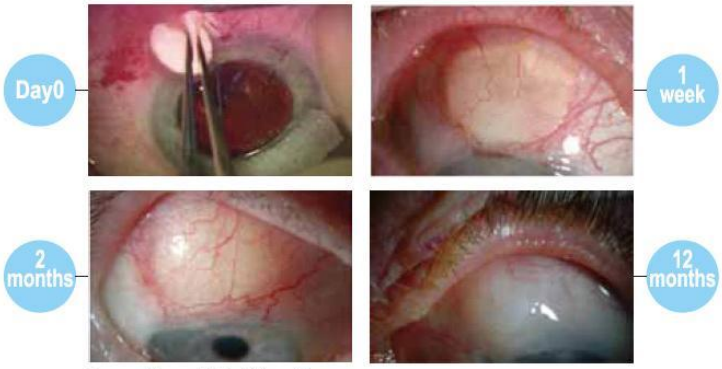

Source: Steven R. Sarkisian, JR
Reprinted With Permission From Dr. Sarkisian

Modulation of wound Healing in
Glaucoma Surgery 2012
Ahmed Aboueleinein

Disadvantage

- Difficult suture lysis

Results

- Almost as equal to Antimetabolities

Anti-VEGF therapy for glaucoma Michael B. Horsley and Malik Y. Kahook

- Current Opinion in Ophthalmology 2010,
- 21:112–117

Summary of Data

	Paracenthesis	Sutures	Antimetabolites	Controlled	Controlled +m.tt.	2nd Surg.
A. Abdelshafek	100%	Non Release 100%	69%	71%	14%	15%
A. Aboueleinein	100%	Non Release 100%	33%	65%	15%	20%
A. Elshiaty	0%	Non Release 100%	51%	71%	17%	12%
A. Khalefa	100%	Non Release 100%	50%	64%	21%	15%
A. Khalil	0%	Non Release 100%	5%	80%	20%	0%
E. Mohammed	100%	Non Release 100%	27%	65%	15%	20%
H. Eissa	100%	Non Release 75%	33%	65%	15%	20%
M. Ibrahim	50%	Release 100%	100%	74%	13%	13%
M. Nassar	100%	Non Release 90%	88%	80%	10%	10%
T. Mokbel	0%	Non Release 90%	54%	70%	20%	10%
			51%	70.5%	16%	13.5%

Summary of Data

- 70% Paracenthesis
- Releasable sutures / suture lysis
- 51% antimetabolites
- Controlled 70.5%
- Controlled with medical treatment 16%
- Second surgery 13.5%

Thank You

Postop Shallow A.C

The depth of A.C &extent of the bleb depends on:

- thickness of the scleral flap.
- I.C injection of viscoelastic
- use of anti metabolites
- tightness of the scleral flap

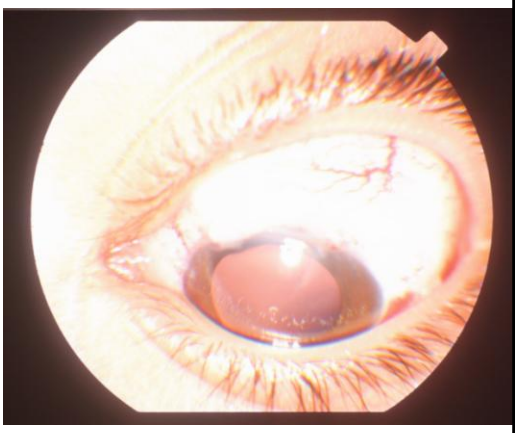

Clinical Classification of Shallow A.C

- Grade 1
- Grade 2
- Grade 3

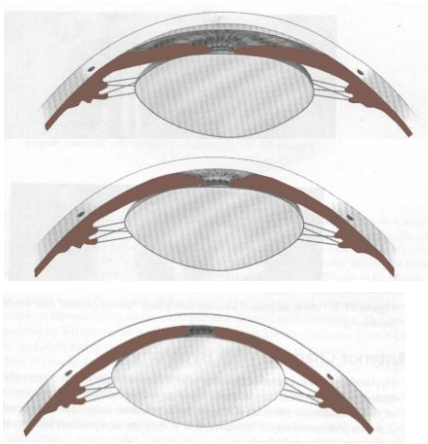

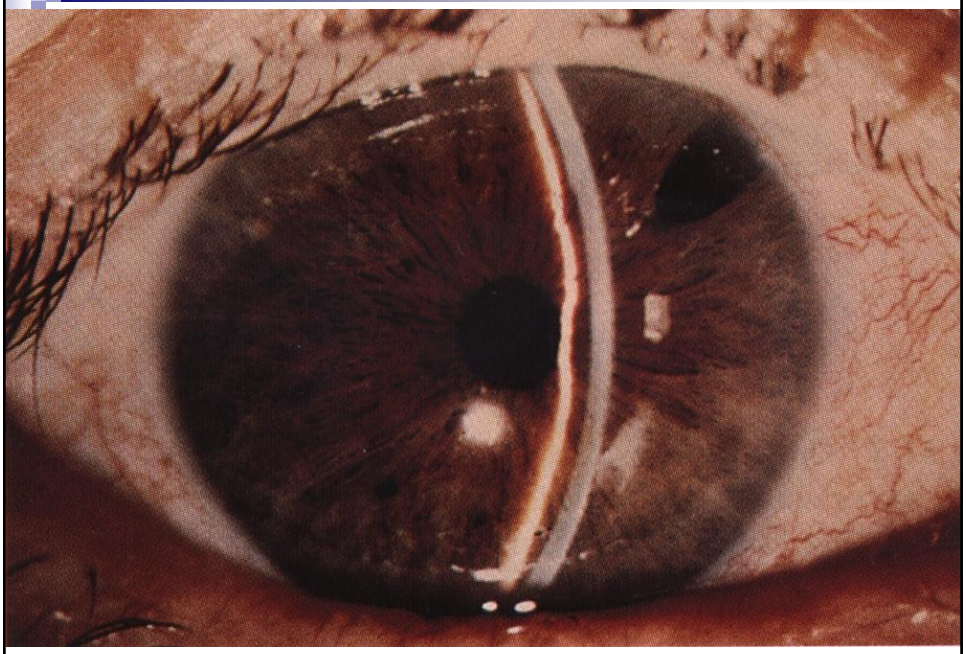

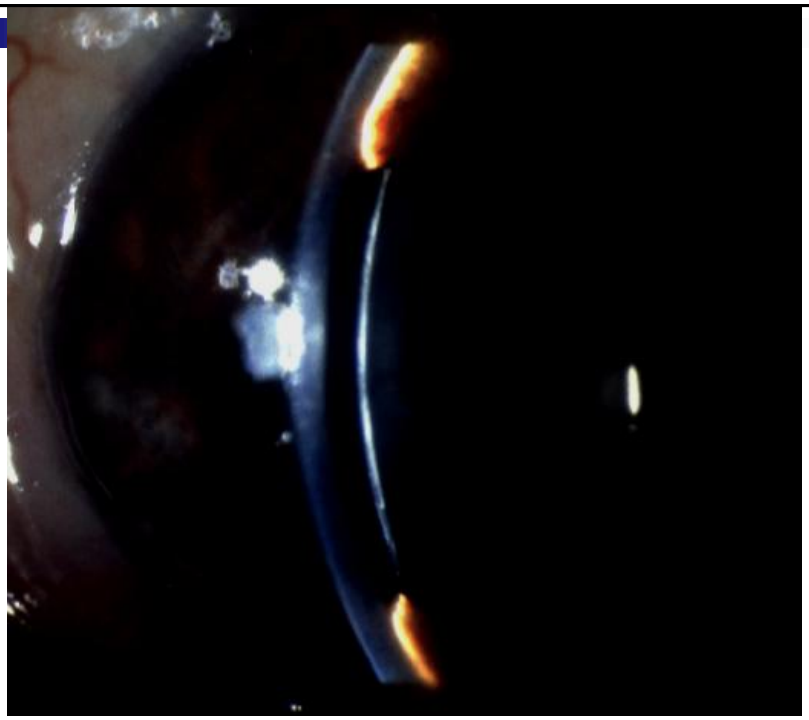

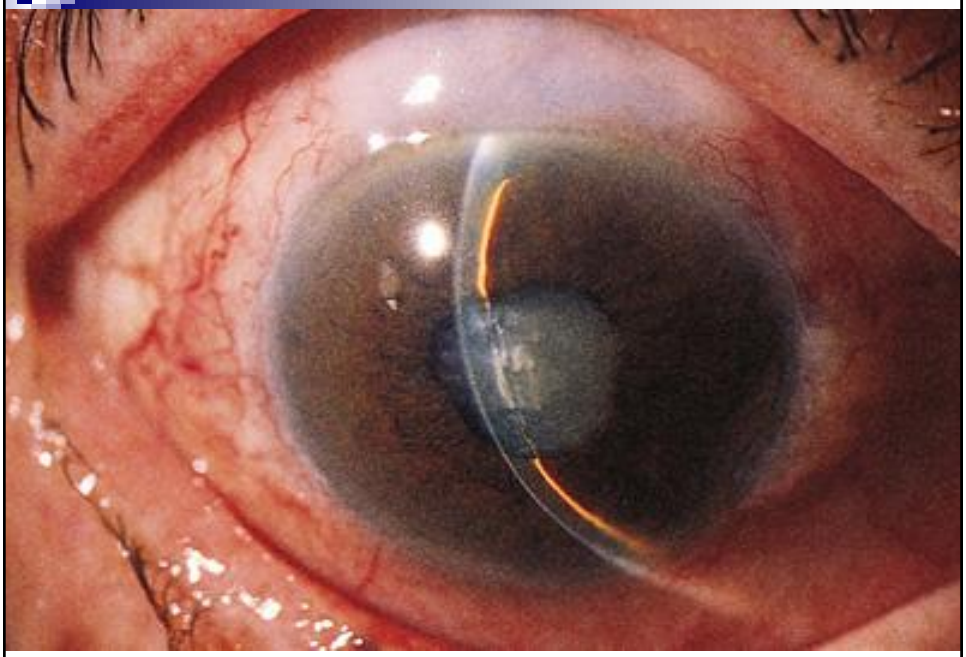

How To Manage Postop. Shallow A.C.?

- First

  Consider Leakage
- Second

  Determine I.O.P.

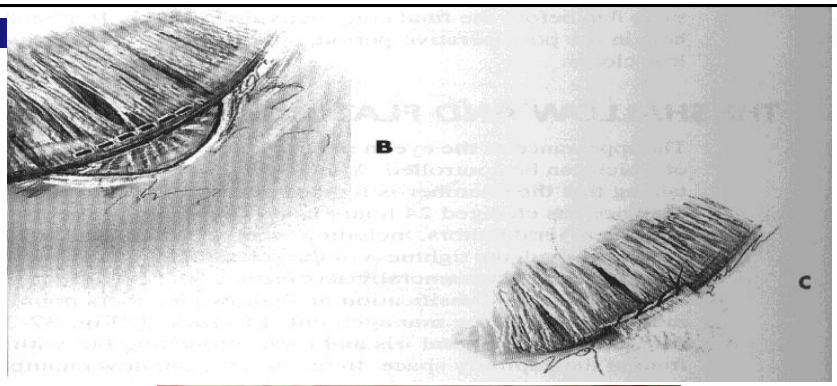

Postop. Shallow A.C Grade& IOP

- Shallow A.C with hypotony.
- Shallow A.C in normotensive & hypertensive eyes.

Shallow A.C With Hypotony

HYPOTNY IOP LESS THAN 8mm H g

- Overfilteration most common in the first few days.
- Choroidal effusions immediate postop.

Shallow A.C With Hypotony Overfilteration

- Management
  - Firm patch ?
  - Large diameter contact lens.
  - Revision of scleral flap sutures when?

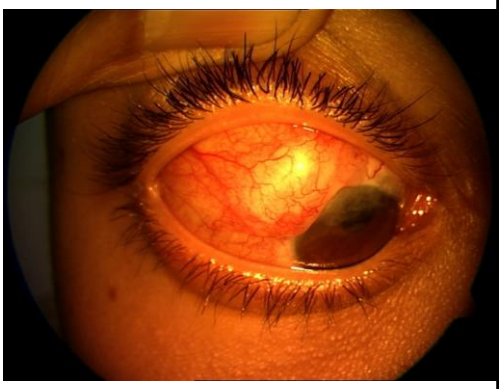

Shallow A.C With Hypotony Choroidal Effusion

CLINICAL PICTURE

- easily visible ora serrata.
- visible choroidal detach.
- kissing.
- presence or absence of leak.
- U.S.

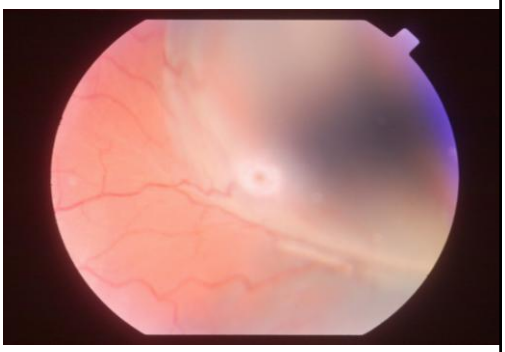

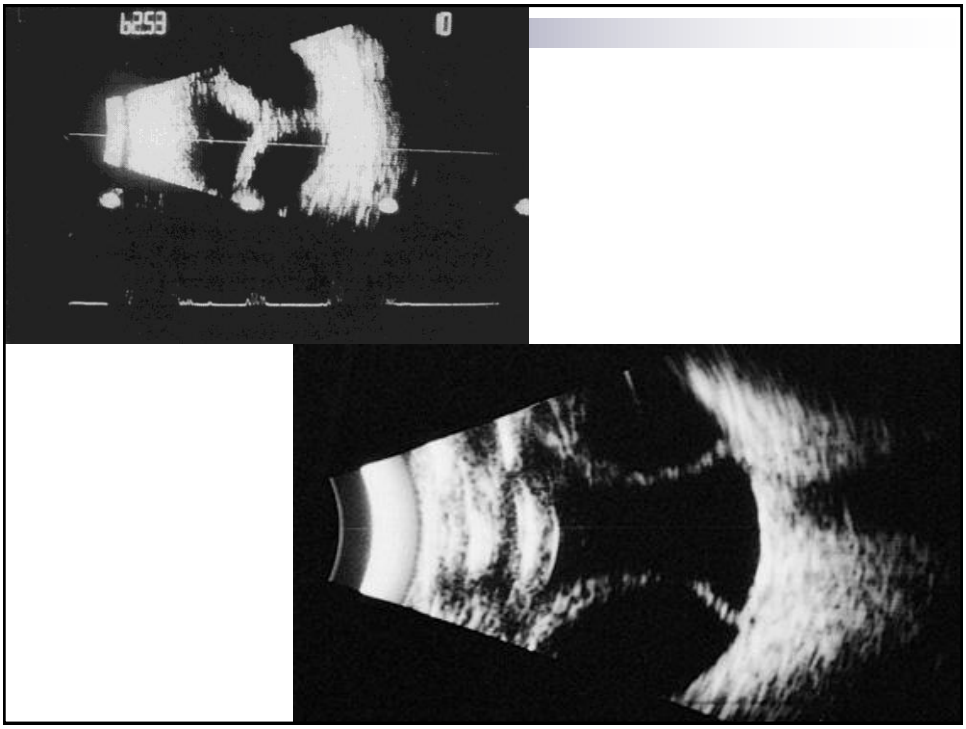

Shallow A.C With Hypotony

CHOROIDAL EFFUSION

Management

- Effusion without conj. Wound leak → conserve unless:

a) Persistant “Kissing choroidals” for long period.
b) Grade III flat AC with compromise of corneal endoth.
c) angle closure gl.→malig. Gl.

Shallow A.C With Hypotony

CHOROIDAL EFFUSION

CONSERVATIVE MEASURES

- Cycloplegics +++
- Steroids
- Large soft C.L.
- Anti-metabolites modify the response to treatment.

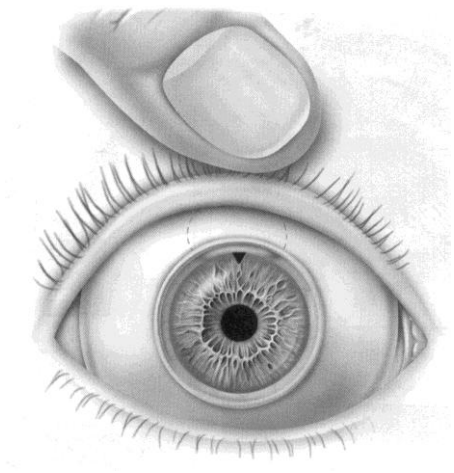

Shallow A.C With Hypotony

CHOROIDAL EFFUSION

SURGICAL MEASURES

- Grade 3:
  Reform the AC making use of the paracenthesis site.
- If the AC is still flat → reform AC after drainage of the suprachoroidal fluid through sclerostomies made 4 mm behind the limbus (over the pars

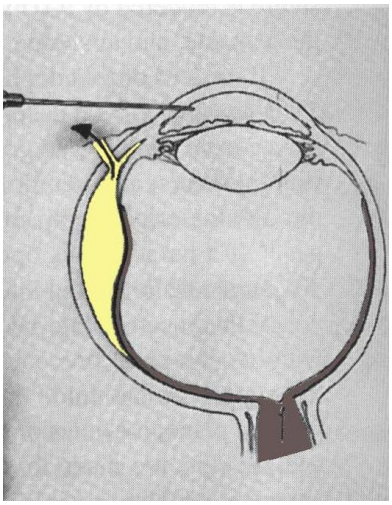

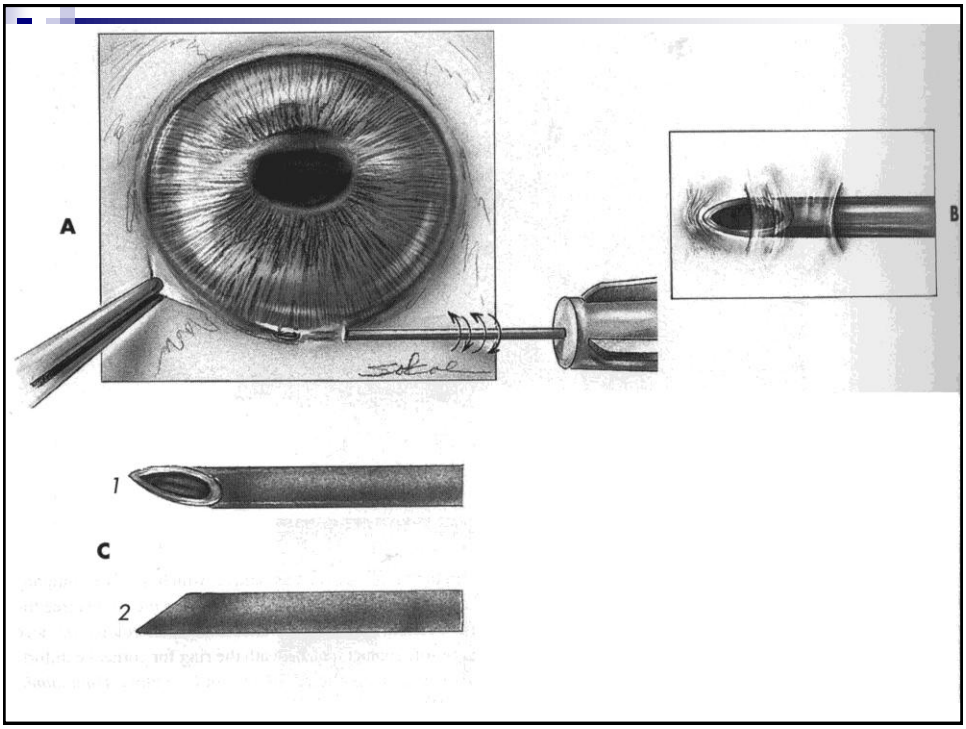

Shallow A.C In Normotensive & Hypertensive Eyes

- Increased volume behind the lens-iris diaphragm either

a) Incomplete iridectomy
b) Misdirection of aq. Into the vitreous.
c) Suprachoroidal hge
d) Vit Hge
e) Expansion of the choroid

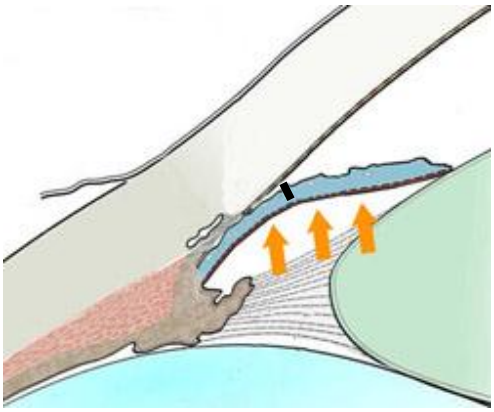

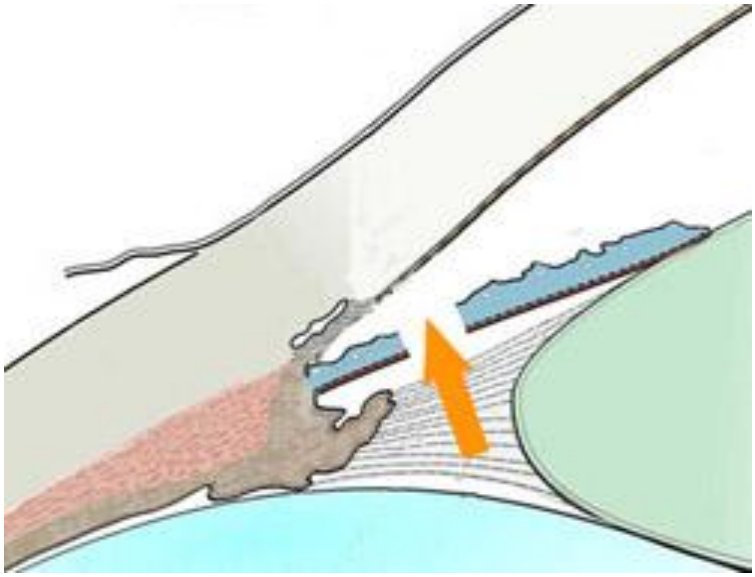

Shallow A.C In Normotensive & Hypertensive Eyes

- Flat AC with normal or high IOP with patent iridectomy

a) Ciliary block

b) Suprachoriodal hge

Shallow A.C In Normotensive & Hypertensive Eyes

CILIARY BLOCK (MALIGNANT GLAUCOMA)

- Atypical angle closure glaucomas.
- Aqueous misdirection.
- Post aq. Entrapment.

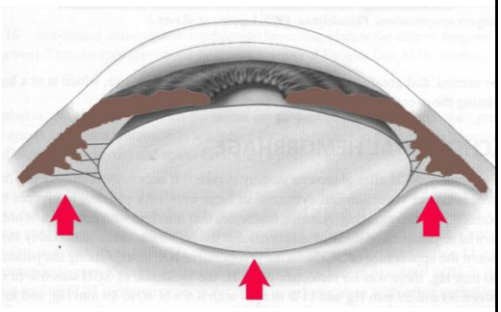

Shallow A.C In Normotensive & Hypertensive Eyes

CILIARY BLOCK (MALIGNANT GLAUCOMA)

Clinical picture

- grade2 or grade3 shallow A.C
- I.O.P early postop 15-20
- adequate bleb
- I.O.P +++ later.
- No possibility of pupillary block.
  i.e. patent P.I

Shallow A.C In Normotensive & Hypertensive Eyes

CILIARY BLOCK
(MALIGNANT GLAUCOMA)

- D.D
  - Non patent P.I
  - Response to cycloplegics
  - Rare spontaneous relief
  - Similarity to angle closure glaucoma
  - No response to P.I or filtering procedure

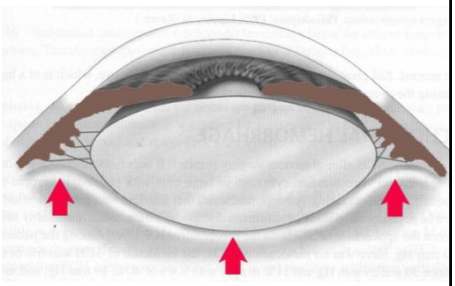

Shallow A.C In Normotensive & Hypertensive Eyes

CILIARY BLOCK (MALIGNANT GLAUCOMA)

- Management
  - Verify patent P.I
  - Discontinue miotices
  - Cycloplegics +++
  - Steroids
  - Ocular hypotensive
  - Wait 5 days

Shallow A.C In Normotensive & Hypertensive Eyes

CILIARY BLOCK (MALIGNANT GLAUCOMA)

- Management (cont.)
  - If no response (50% of cases)
  - Surgical intervension

1. Needle asperation of vit. through P.P
2. P.P vitrectomy
3. Aphakic or pseudophakic eyes with retained posterior capsule YAG of the hyaloid face.
4. Sacrifice the lens when?

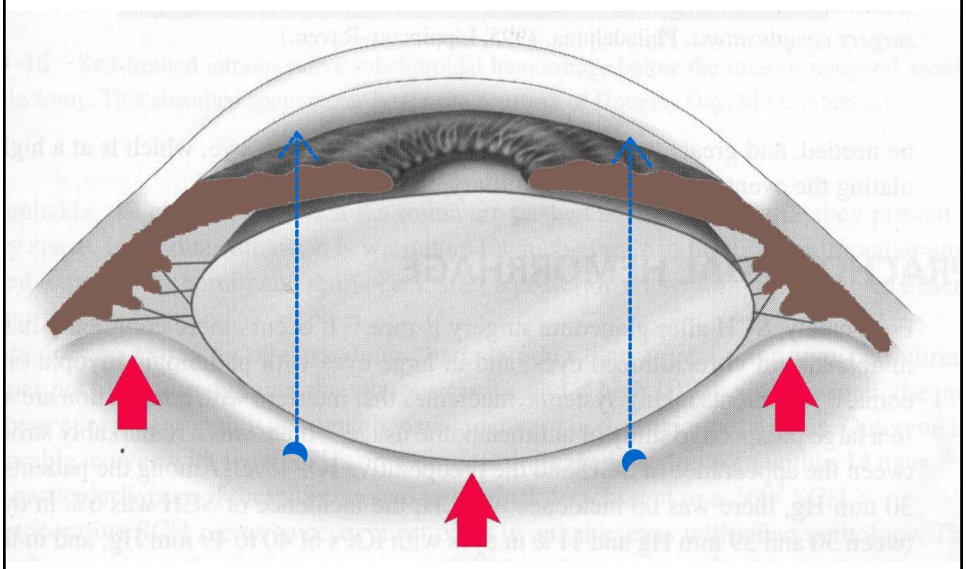

Shallow A.C In Normotensive & Hypertensive Eyes

SUPRACHORIODAL HGE

- Rare after glaucoma surgery
- More common in trauma, aphakia, vitrectomized eyes.
- High risk of anticoaglants
- Preop. I.O.P above 30 mm Hg
- Ax. Length more than

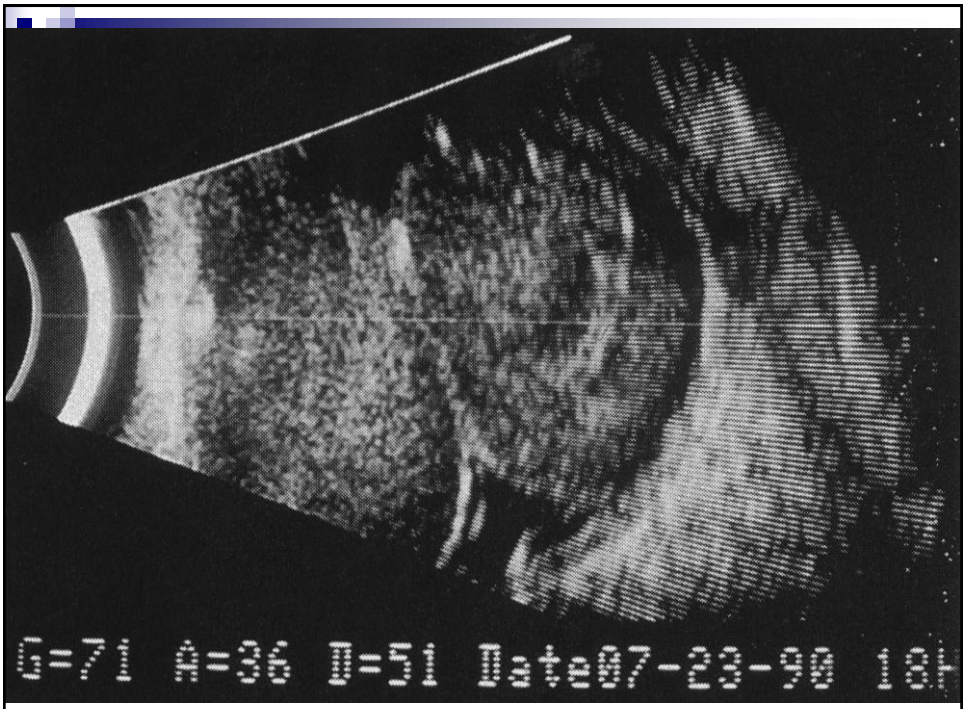

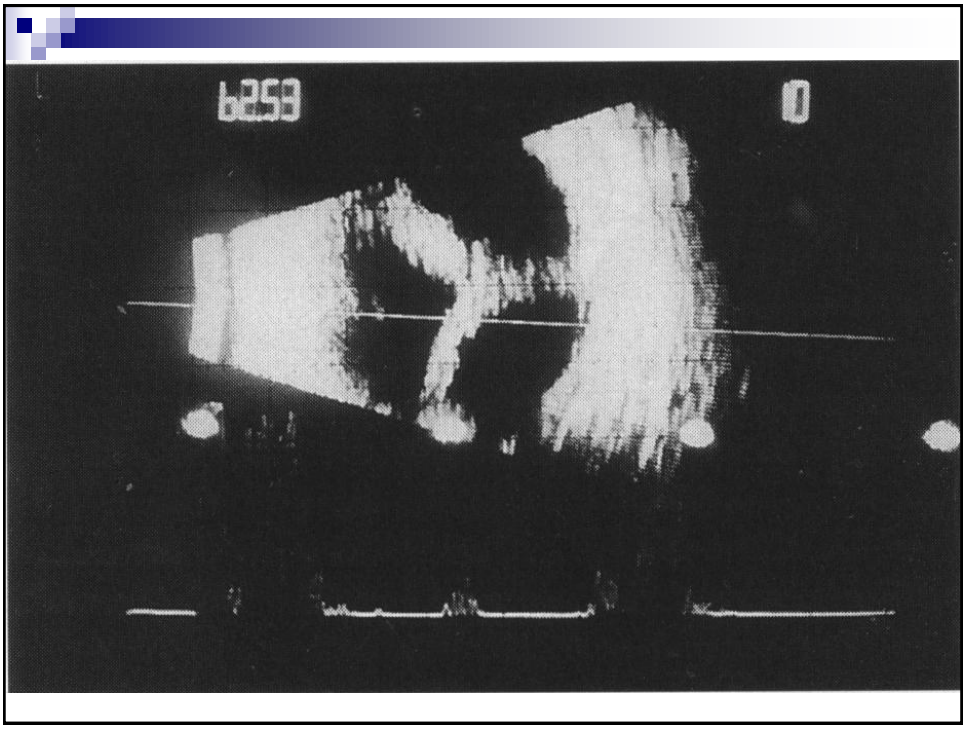

Shallow A.C In Normotensive & Hypertensive Eyes

SUPRACHORIODAL HGE

- Management
  1. Medical treatment until when?
  2. Surgical treatment when?
     - Large scleral incision guided by U.S.
     - precautions:
       - Avoid touching the choroid
       - Don’t try to pull the clot, express gently.
       - Reform the A.C
  3. 2 mm sclerstomy when?

Interaoperative Shallow A.C

- Ciliary block glaucoma (B.S.S injected permeates to the vitreous)
- Sturge-Weber syndrome

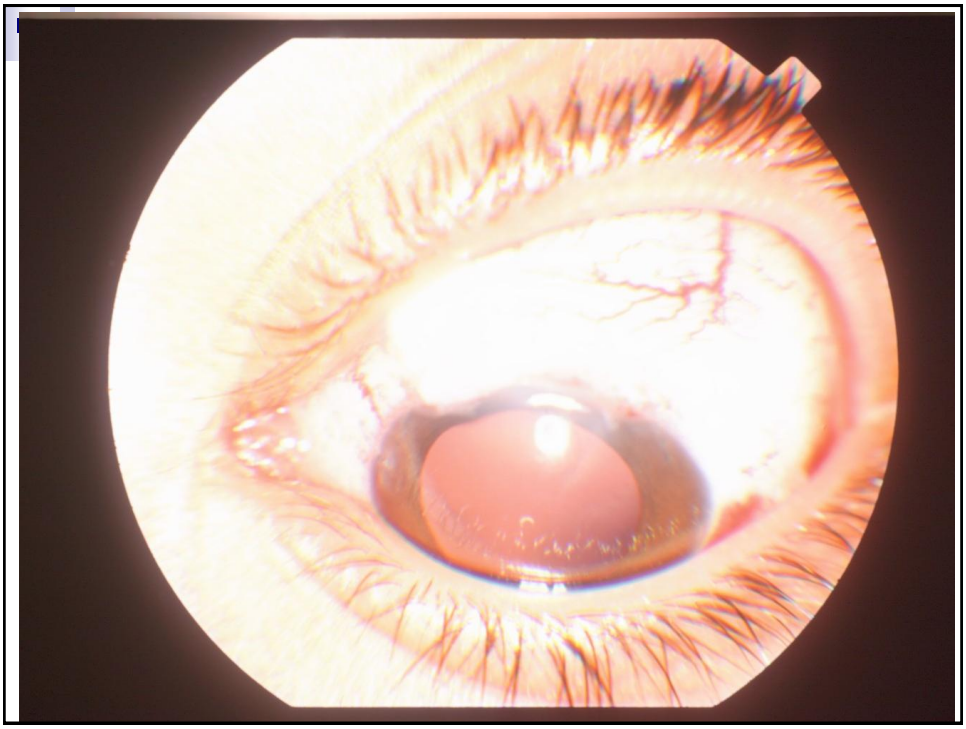

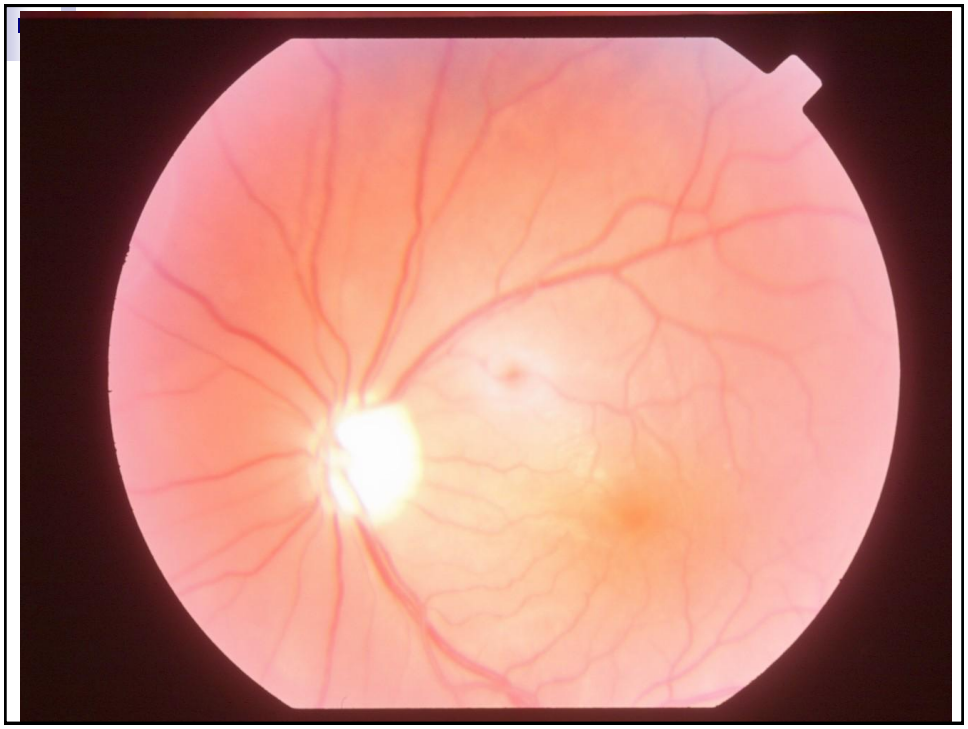

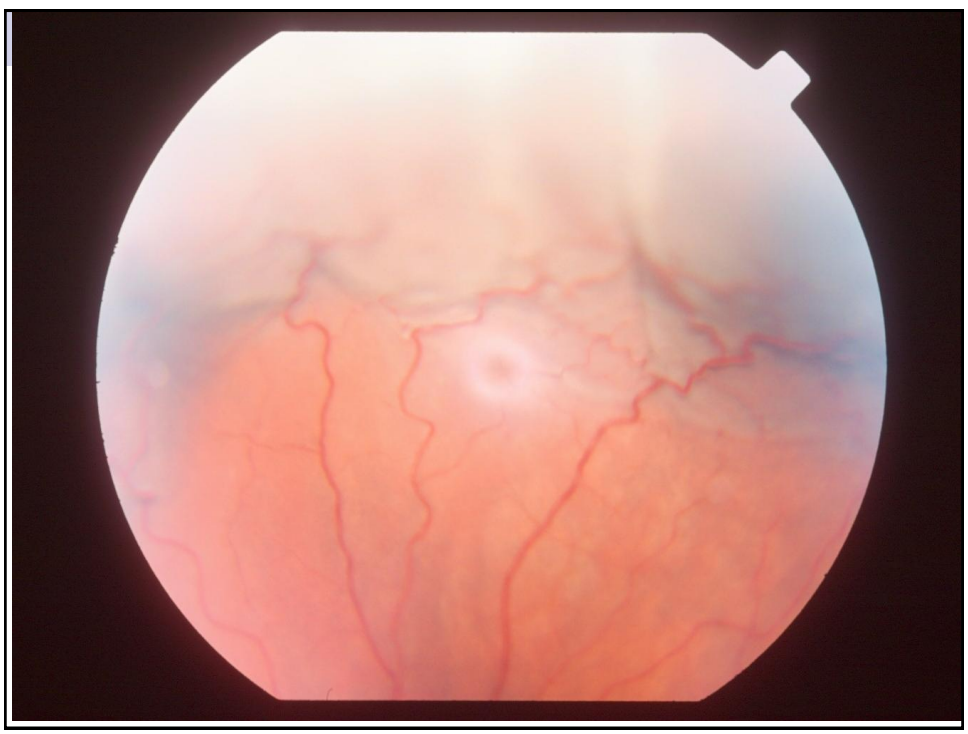

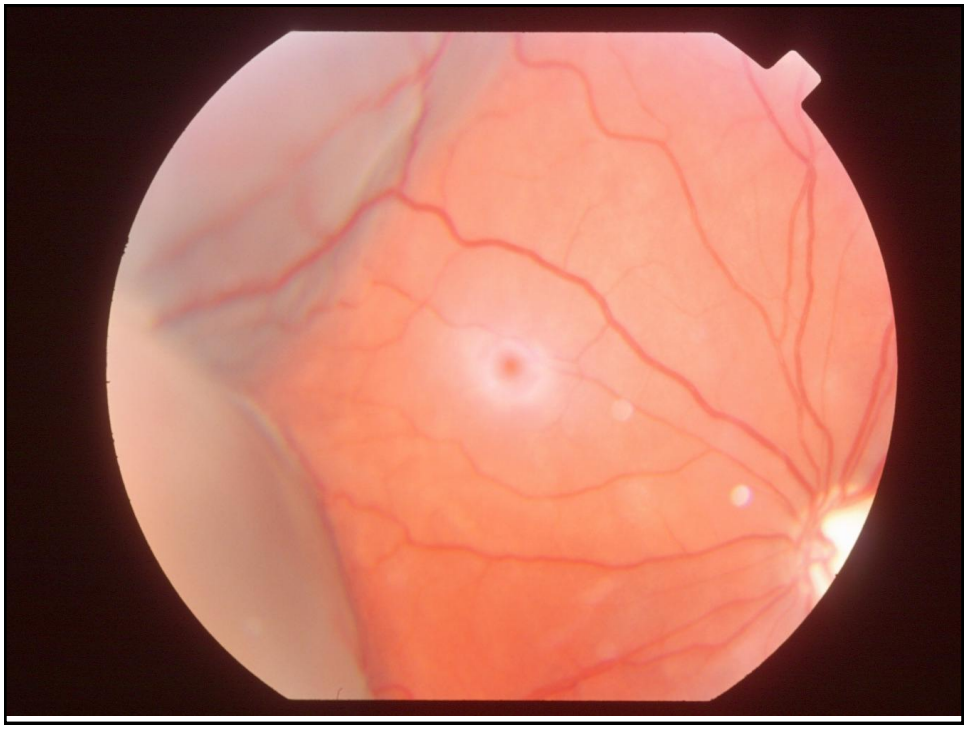

TABLE 3. MOORFIELDS EYE HOSPITAL'S INTRAOPERATIVE, SINGLE-DOSE, ANTISCARRING REGIMEN*†

Patient Category	Characteristics	Regimen
Low-Risk	No risk factors Topical medications (eg, beta-blockers, pilocarpine) Afro-Caribbean origin and elderly <40 years of age with no other risk factors	Nothing or intraoperative 5-FU 50 mg/mL†‡§ for 5 minutes, as per the Moorfields "More Flow" study
Intermediate-Risk	Topical medications (eg, adrenaline) Previous cataract surgery without conjunctival incision (capsule intact) Several low-risk factors Combined glaucoma filtration surgery/cataract extraction Previous conjunctival surgery (eg, squint surgery, retinal detachment surgery, trabeculotomy)	Intraoperative 5-FU 50 mg/mL†‡ for 5 minutes or MMC 0.2 mg/mL§ for 3 minutes, as per the Moorfields "More Flow" study
High-Risk	Neovascular glaucoma Chronic, persistent uveitis Previous failed trabeculectomy/tubes Chronic conjunctival inflammation Multiple risk factors Aphakic glaucoma	Intraoperative MMC 0.5 mg/mL§ for 3 minutes (a tube may be more appropriate in many of these cases, combined with MMC)

Shallow anterior chamber

Cause	IOP	Bleb	Seidel test
Wound leak	Low	Poor	Positive
Overfiltration Choroidal Effusion	Low	Good	Negative
Malignant glaucoma	High	Poor	Negative
Intraop. Choroidal expansion Ciliary block	Normal or high	Poor	Negative

Thank You